

**Chronic Traumatic Encephalopathy:
Chronic Degenerative Disease**

By: Rebecca Lane
Prepared for: Edith Kunszt, CNP, RNCP, DiHom
Date: December 9, 2010
Course: Nutritional Pathology

Chronic: Chronic Traumatic Encephalopathy (CTE)

Introduction

Chronic Traumatic Encephalopathy (CTE) is a progressive, degenerative disease found in primarily in professional athletes and soldiers who have been subjected to repetitive head trauma, including concussions, subconcussive blows and blast injuries. It results in characteristic degeneration of brain tissue and abnormal tau and TDP-43 protein accumulation with neurofibrillary tangles, glial tangles, and neurophil threads throughout the brain in the relative absence of β -amyloid deposits. Although similar to Alzheimer's disease and ALS, CTE is pathologically distinct (tau pathology is not found in sporadic ALS and β -amyloid deposits are found in Alzheimer's, in CTE they are in much lower concentrations), and it is the only known preventable cause of dementia. (McCrorry, 467)

Symptoms: Early on, CTE sufferers may display symptoms such as memory impairment, emotional instability, erratic behaviour, depression and problems with impulse control. CTE may eventually progress to full-blown dementia. There are also physical symptoms including disturbed gait and coordination, slurred speech and tremors. (McCrorry, 467) Recent studies have determined that several individuals previously diagnosed with amyotrophic lateral sclerosis (ALS) were afflicted with CTE because of elevated tau protein and TDP-43 protein in brain and spinal cord tissue. (CSTE, Aug. 2010) The severity of the disorder seems to correlate with the length of time engaged in the sport and the number of traumatic injuries. (McKee (2009), 710)

- **Pre-Clinical state** – players become *increasingly vulnerable to blows*, being readily knocked down and taking longer to recover. Initial symptoms include *depression, memory loss, irritability, outbursts of aggression, and confusion*. It has been suggested that if players cease professional play at this stage then the neurological signs progress for a year or two then become stationary. (McCrorry, 468-469) The first symptoms of CTE were noticed at ages ranging from 25 to 76 years (mean 42.8 years). (McKee (2009), 710)
- **Clinical state** – the most common clinical symptom is *slurred speech* (resulting from defects in motor nerves) accompanied with *gait ataxia or disequilibrium*, combined with persistent and disabling *headaches*. A fine and intermittent *tremor* occurs in less than 50% of cases. (McCrorry, 469)
- **Dementia** – *dementia* generally shows up 10 – 20 years after retirement.
- **Behavioural signs** – early symptoms include *emotional instability, euphoria and hypomania*. At the same time, often individuals show an *increased sensitivity to the affects of alcohol*. Late neurobehavioural symptoms *psychomotor retardation*, exacerbation of premorbid personality traits, *aggression, suspiciousness, childishness, loquacity and restlessness*. As CTE progresses, there is difficulty with *impulse control, disinhibition, irritability, inappropriateness* and explosive outbursts of *aggression*. CTE individuals frequently have **diminished insight** combined with uninhibited **violent behaviour and paranoia**. Occasionally, CTE individuals exhibit *hyperorality* and *hypersexuality* as a result of injury to the temporal lobes. (McCrorry, 470)

Diagnosis: Autopsy of brain and spinal column tissue presents dramatically high levels of tau protein and TDP-43 especially in the frontal and temporal cortices, medial temporal lobe, basal ganglia, diencephalon, and brainstem. (McKee, Abstract) Currently there is no ability to diagnose the disease until morbidity.

Treatment: Currently there is no treatment for CTE. However, the consensus among experts is that brain trauma is almost certainly not solely responsible for the disease. Genetic factors lead to susceptibility, with concussions serving as a catalyst. Researchers expect that soon athletes will be tested for the gene that leaves them vulnerable. (Schwarz, Abstract) Another hypothesis is the presence of a dominant virus.

Further research is currently being undertaken. The existence of a long period between the initial traumatic injury and the onset of CTE gives a large timeframe for implementing therapeutic measures to block the neurodegenerative cascade of cumulative MTBI.

Modern Classification of Disease

Constitutional: An athlete or soldier is susceptible to developing CTE if they have a prior history of concussions, subconcussive blows and blast injuries. Several factors have been determined to make some individuals more vulnerable to concussion and subconcussive blows than others:

1. **Genetic protein marker Apolipoprotein E:** ApoE is a fat-binding protein that is essential for a multitude of biological functions. It is involved with neuronal repair and antioxidant activity. Recent efforts have focused on the **possible** roles of ApoE-E4 and the ApoE promoter gene in concussion risk. Published studies have demonstrated that ApoE4 is a risk factor for adverse outcome following all levels of brain injury. (Kutcher, 18) However, the significance of apolipoprotein (Apo) E4, ApoE promoter gene, Tau polymerase and other genetic markers in the management of CTE is unclear at this time. (McCrary (2009), 758)
2. **Family History:** There is evidence to suggest that if parents and relatives have a history of multiple concussions with decreasing force requirements, escalating symptoms, changing personality, retirement from contact sports, and prolonged cognitive and mood effects, the risk to the offspring is greater that they will be predisposed. (Kutcher, 19)
3. **Fatigue:** Athletes are more likely to be concussed after significant physical exertion, especially in the setting of inadequate hydration or caloric intake. A second, more speculative, role for physical fatigue in increasing concussion risk is based on the observation that physical exertion to the point of fatigue can lead to slowed reaction time. An athlete with slowed reaction time will, naturally, have a more difficult time avoiding contact and may be at a higher risk of concussion as

a result. It also is important to note that physical exertion alone has been shown to produce concussive symptoms. (Kutcher, 19)

4. **Cumulative Exposure to Concussion or Subconcussive Blows to Brain and/or Spinal Cord:** Research is showing that repeated lower-impact, or "subconcussive," blows can be damaging. The more the skull is shaken, and the brain jostled, the greater the likelihood of developing CTE.
5. **Steroid use** – potential that CTE may be enhanced by the use of steroids since many of the players whose brains have been scanned also used the drugs. (Gladwell article)

Systemic:

Nervous system – Modern neuroradiological imaging techniques have been unsuccessful in demonstrating any evidence of CTE. However, common abnormalities noted during radiological (CT scans and MRI) and radionuclide (Xenon-133) assessments include:

- **Reductions in cerebral blood flow,**
- Evidence of **compromise of the blood-brain barrier,**
- **Reduction in brain weight** – generally mild and associated with atrophy of the frontal, parietal and temporal lobes. With increasing severity of the disease, atrophy of the hippocampus, entorhinal cortex, and amygdala may become evident, (McKee (2009), 718)
- **Enlargement of the lateral and third ventricles of the brain** – frequently dilated, (McKee (2009), 718)
- **Thinning of the corpus callosum,** (McKee (2009), 718)
- **Substantia nigral degeneration** (associated with Parkinsonian features),
- **Scarring and neuronal loss of the cerebellar tonsils,**
- **Neurofibrillary tangles** (tau and TDP-43 proteinopathy as well as astrocytic tangles and neurophil neurites) in the brain and spinal cord – characteristically irregular in distribution with multifocal patches of dense NFTs, (McCrary, 468-472)
- **White matter changes and abnormalities** - Tau-positive fibrillar astrocytic tangles are found in the white matter, but the major abnormality is that of dotlike or spindle-shaped tau-positive neurites. The shape of the tau-immunoreactive neurites is distinct from the predominantly threadlike forms found in Alzheimer's and suggests an axonal origin (they are shorter and less prominent than in AD). Other abnormalities include small arterioles with thickened fibrohyalinized walls with perivascular hemosiderin-laden macrophages, widened perivascular spaces, and white matter rarefaction, (McKee (2009), 729)
- **Fenestrated cavum septum pellucidum (CSP)** (a septum pellucidum that has a separation between its two leaflets) – the separation shows serial enlargement on repeat scans and is potentially associated with behavioural disturbances, (McKee (2009), 709)
- **Corticospinal tract degeneration,** (McKee, 918) and

- **Axonal injury and motor neuron loss** - Neuronal loss and gliosis most commonly accompany neurofibrillary degeneration and are pronounced in the hippocampus, the entorhinal cortex, and amygdala. (McKee, 918)

Digestive system – Nausea, swallowing difficulties and vomiting appear as a result of dysautoregulation of the nervous system rather than digestive system malfunctions.

Cardiovascular system – Reduction in cerebral blood flow caused by release of excitatory amino acids (EAAs) – glutaminemediated N-methyl-D aspartate (NDMA). The injury induced by these EAAs results in post-traumatic dysautoregulation and a subsequent decrease in cerebral blood flow. (Aloi, 2) With repeated concussion and subconcussive blows to the head, cerebral blood flow remains reduced.

Immune/Lymphatic system – The cumulative damage from repetition of the neurochemical cascade of concussion and subconcussive blows causes free radical accumulation. Inability to reduce free radicals is an important source of secondary injury in the traumatized brain. In addition, inflammation, glutamate excitotoxicity, and oxidative stress may trigger the molecular pathways leading to neuronal degeneration in CTE. Their contributions to the molecular cascades in CTE remain to be explored. (McKee, 927)

Musculoskeletal system – Tremors, altered gait, swallowing difficulties and slurred spastic speech caused by damage to motor neurons rather than muscular damage.

Histopathic: The pathological changes of CTE consist of numerous tau-positive neurofibrillary tangles, neuropil neurites, and astrocytic tangles in the frontal, temporal, and insular cortices, subcortical white matter, diencephalon, basal ganglia, and brainstem along with extensive TDP-43 immunoreactivity. (McKee, 921) The TDP-43 positive inclusions and tau tangles are usually found in discrete sections of the brain.

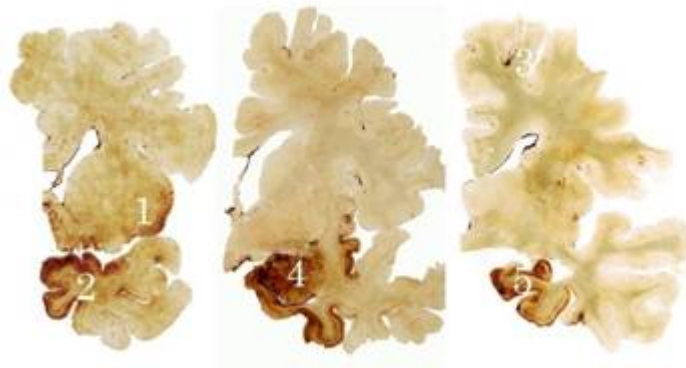
- **TAR DNA-binding protein 43 (TDP-43)** - is a cellular protein which in humans is encoded by the *TARDBP* gene. It is a transcriptional repressor that binds to chromosomally integrated TAR DNA. A cleaved form of the TARDBP gene, called pathogenic tau-negative ubiquitin-positive TDP-43, is the major disease protein in CTE.

TDP-43 affects the frontal and temporal cortices, medial temporal lobe, basal ganglia, diencephalon, and brainstem. It also extends to the spinal cord and is associated with motor neuron disease with symptoms of profound weakness, atrophy, spasticity and twitches several years before death. (McKee, 918) It was originally thought to be a marker for ALS but has now been found in a variety of other neurodegenerative disorders.

- **Tau Proteins** - are proteins that stabilize microtubules. They are abundant in neurons in the central nervous system and are less common elsewhere. When tau proteins are defective, and no longer stabilize microtubules properly, they form

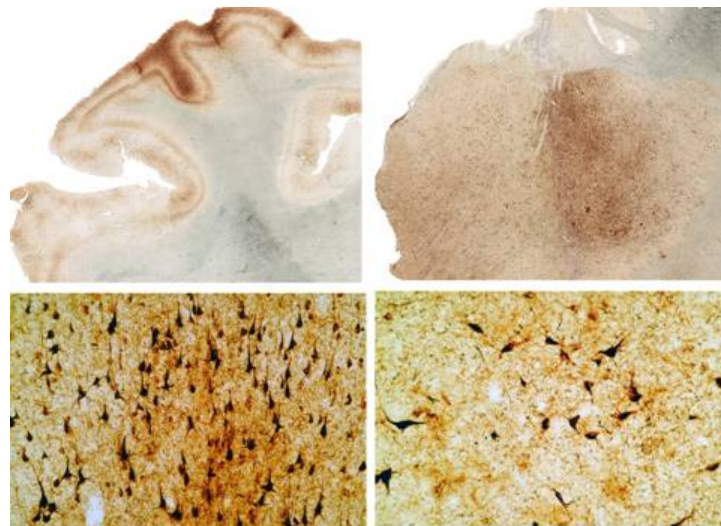
tangles. Tangles are formed by hyperphosphorylation of the tau, causing it to aggregate in an insoluble form.

- **Spindle-shaped and threadlike neurites** (McKee (2009), 709)
- **Loss of myelin and axons with astrocytosis and formation of astrocytic tangles** – in individuals with CTE who also showed motor neuron disease in the last stages of their life, both the brain and spinal cord showed marked myelin and axonal loss with astrocytosis and loss of anterior horn cells. They also showed marked atrophy and gliosis of ventral roots. With those who did not display motor neuron disease, there is only mild degeneration. (McKee, 923)



The figure above shows dense tau deposits (brown) in the insula (1), temporal (2) and frontal (3) cortices, amygdala (4) and hippocampus (5) in the absence of beta amyloid plaques. A normal control brain would not show any brown discoloration.

(Case Study, Lou Creekmur)



The figure above shows brain tissue from Thomas McHale, a former Tampa Bay Buccaneer who died at age 45 from a drug overdose.

- Top left: Whole mount section of neocortex immunostained for tau protein showing extensive deposition of tau protein as neurofibrillary tangles throughout the neocortex
- Bottom left: High magnification photomicrograph of neocortex showing innumerable tau immunoreactive neurofibrillary tangles and neuropil neurites
- Top right: Whole mount section of amygdala immunostained for tau protein showing dense, patchy deposition of tau protein
- Bottom right: High magnification photomicrograph showing tau immunoreactive neurofibrillary tangles and neuropil neurites in the amygdala
(Case Study, Thomas McHale)

During a concussion or traumatic brain injury, the brain and spinal cord undergo shear deformation, which causes elongation or stretching of axons. This traumatic axonal injury also disturbs the cytoskeleton causing damage to microtubules and neurofilaments and reorganization of neurofilament proteins. Because of its capacity to bind and stabilize the neurofilament mRNA, TDP-43 as well as tau proteins play a critical role in mediating the response of the neuronal cytoskeleton to axonal injury. (McKee, 927)

Further research needs to determine whether traumatic axonal injury may also accelerate TDP-43 accumulation, aggregation, and dislocation to the cytoplasm and thereby enhance its neurotoxicity. (McKee, 927)

Biochemic Markers: Evidence from human and animal studies in more severe traumatic brain injury demonstrates induction of a variety of genetic and cytokine markers. However, whether such markers are conclusively involved with CTE is not known at this time:

- ***Astroglial protein (S100B)*** - S100B may indicate brain injury, but diagnostic tests for it are still experimental. S100 protein is released from astrocytes. (Aloi, 7);
- ***Glial fibrillary acidic protein (GFAP)*** - measured in serum can be used as a biochemical brain damage marker;
- ***Cleaved tau protein (CTP)*** - Cleaved tau protein (CTP), found in axons, is presumed to be released after MTBI when diffuse axonal injury has occurred. This marker may be useful in combination with S100B protein. (Aloi, 7);
- ***Insulin-like growth factor-1(IGF-1)***;
- ***IGF binding protein-2***;
- ***Fibroblast growth factor***;
- ***Copper-zinc superoxide dismutase-1 (SOD-1)***;
- ***N-methyl-D aspartate (NDMA)*** - Excitatory amino acids (EAAs) are present after brain trauma – glutamine mediated N-methyl-D aspartate (NDMA) (Aloi, 2), though their specific role in CTE is yet unexamined;
- ***N-acetylaspartate (NAA)***, a neuronal marker;
- ***Nerve growth factor***; (McCrory (2009), 758)
- Increases in ***creatine kinase isoenzyme BB*** and increased ***cerebrospinal fluid protein***, and ***neuron-specific enolase*** (McCrory, 472).

Deficiency:

- Zinc induces depletion and aggregation of endogenous TDP-43 (Wikipedia)
- Proper hydration – dehydration decreases amount of cerebral spinal fluid (CSF), which absorbs shock and trauma to the brain, and also increases potential for fatigue which has an impact on the incidence of concussion.
- Caloric intake – insufficient caloric intake increases potential for fatigue which has an impact on the incidence of concussion.
- Antioxidants – insufficient antioxidant concentrations would not support the response to inflammation, glutamate excitotoxicity, and oxidative stress, increasing the concentration of free radicals and therefore the amount of residual damage.
- Levels of dopamine and serotonin are reduced in the cerebrospinal fluid of MTBI victims. This is an area for further research for therapeutic consideration.

Occupational: Verified CTE has been reported in (although the list is almost certainly more inclusive):

- professional and amateur athletes including: boxers (related disease dementia pugilistica), wrestlers, football, soccer, and most recently in hockey players; and
- military veterans who have suffered from multiple concussions and/or head trauma, including combat-related injuries during deployment to major conflicts and participation in competitive sports. (McKee, 920)

Accidental: Verified CTE has been reported in epileptics, head bangers, and domestic abuse victims

Infections: Research is currently being undertaken to determine if CTE could be the result of a dominant virus. No conclusive statements are yet available. (Medical Device Daily, 4)

Conclusion

During a traumatic brain injury, the brain and spinal cord undergo a severe shearing force which produces

1. a transient elongation or stretching of axons and
2. shearing of the septum pellucidum which may develop into an enlarged cavum septum pellucidum and, if severe or repeated, may produce fenestrations.

Axonal injury causes dissolution of microtubules and neurofilaments and reorganization of neurofilament proteins. Because of its ability to bind to neurofilament mRNA and stabilize the mRNA transcript, TDP -43 plays a critical role in mediating the response of the neuronal cytoskeleton to axonal injury. Repeated axonal damage may accelerate TDP-43 accumulation, aggregation, and dislocation to the cytoplasm and thereby enhance its neurotoxicity. (McKee, 927)

The patchy, irregular deposition of the neurofibrillary tangles suggests that their distribution is a result of direct injury from blows to the side or top of the head. Further research needs to be taken to explore the possibility that ischemia may contribute to the development of tau pathology. Further, damage to the blood-brain barrier and release of local neurotoxins may explain the tendency toward extensive tau proteinopathy. (McKee (2009), 731)

There are multiple other biological mechanisms by which repetitive head injury trauma may trigger the molecular pathways leading to neuronal degeneration in CTE, including inflammation, glutamate excitotoxicity, and oxidative stress. How these factors relate to the changes in CTE have yet to be researched.

One of the key features of CTE is that the disease continues to progress decades after the activity that produced traumatic injury has stopped. It is most likely that multiple pathological cascades continue to exert their effects throughout the individual's lifetime once they are triggered by repetitive trauma; the longer the survival after the initial events and the more severe the original injuries, the greater the severity of the neurodegeneration. It is clear that neuronal loss, cerebral atrophy, and ventricular enlargement all increase with longer survival and greater exposure to repetitive trauma. (McKee (2009), 732)

Another area of future research is determining specific risk factors (including genetic) and the potential for therapeutic intervention in CTE. The existence of a long period between the initial traumatic injury and the onset of CTE gives a large timeframe for implementing therapeutic measures to block the neurodegenerative cascade of cumulative MTBI. (McKee, 927)

Obviously, the easiest way to decrease the incidence of CTE is to decrease the number of concussions in sport by changing the rules so that fighting, massive hits, and continual pounding no longer play such an important role.

References

- “Aethlon to collaborate on athletes’ brain tissue study”. *Medical Device Daily*, (November 2009) 13(214): 4.
- Aloi, MD, RDMS. Mara S. (2008 May/June) “Pediatric Concussions” *Pediatric Emergency Medicine Reports* 9 (3): 9-13.
- Case Study: Lou Creekmur, Center for the Study of Traumatic Encephalopathy.
<http://www.bu.edu/cste/case-studies/lou-creekmur/>
- Case Study: Thomas McHale, Center for the Study of Traumatic Encephalopathy.
<http://www.bu.edu/cste/case-studies/thomas-mchale/>
- Centre for the Study of Traumatic Encephalopathy (August 17, 2010).”Boston University and Department of Veterans Affairs Researchers Discover Brain Trauma in Sports May Cause a New Disease That Mimics ALS”, Press Release.
- DiFori, M.D., FACSM. John P. (2010) “New Techniques in Concussion Imaging” *Current Sports Medicine Reports* 9 (1): 35-39.
- Dusick, Joshua R. Glenn, Thomas C. (2007) “Increased pentose phosphate pathway flux after clinical traumatic brain injury: a [1,2-¹³C₂] glucose labeling study in humans.” *Journal of Cerebral Blood Flow and Metabolism* 27: 1593-1602.
- Giza CC, Hovda DA. (2001) “The neurometabolic cascade of concussion.” *Journal of Athletic Training* 36: 228-235.
- Gladwell, Malcolm (2009). “Offensive Play”. *New Yorker* 85 (33)
- Hovda DA, Lee SM, Smith ML, et al. (1995) “The neurochemical and metabolic cascade following brain injury: moving from animal models to man.” *Journal of Neurotrauma* 12:903-906.
- Kutcher, Jeffrey S. (2010) “At-Risk Populations in Sports-Related Concussion” *Current Sports Medicine Reports* 9(1): 16-20.
- McCrorry, MBBS, PhD. Paul (2005 March) “Summary and Agreement Statement of the 2nd International Conference on Concussion in Sport, Prague 2004” *Clinical Journal of Sports Medicine*. 15(2): 48-58.
- McCrorry P, Zazryn T, Cameron P (2007). “The Evidence for Chronic Traumatic Encephalopathy in Boxing”, *Sports Medicine* 37 (6): 467-476

- McCrary, P. Meeuwisse, W. (2009) "Consensus statement on concussion in sport – The 3rd International Conference on concussion in sport, held in Zurich, November 2008." *Journal of Clinical Neuroscience* 16: 755-763.
- McKee, MD, Ann C. Robert C. Cantu, MD, Christopher J. Nowinski, AB, E. Tessa Hedley-Whyte, MD, Brandon E. Gavett, PhD, Andrew E. Budson, MD, Veronica E. Santini, MD, Hyo-Soon Lee, MD, Caroline A. Kubilus, and Robert A. Stern, PhD (July 2009). "Chronic Traumatic Encephalopathy in Athletes: Progressive Tauopathy After Repetitive Head Injury". *J Neuropathol* 68 (7): 709-735.
- McKee, MD, Ann C. Brandon E. Gavett, PhD, Robert A. Stern, PhD, Christopher J. Nowinski, AB, Robert C. Cantu, MD, Neil W. Kowall, MD, Daniel P. Perl, MD, E. Tessa Hedley-Whyte, MD, Bruce Price, MD, Chris Sullivan, Peter Morin, MD, PhD, Hyo-Soon Lee, MD, Caroline A. Kubilus, Daniel H. Daneshvar, MA, Megan Wulff, MPH, and Andrew E. Budson, MD (September 2010). "TDP-43 Proteinopathy and Motor Neuron Disease in Chronic Traumatic Encephalopathy". *J Neuropathol* 69 (9): 918-929.
- Omalu BI, DeKosky ST, Minster RL, et al. (2005) "Chronic traumatic encephalopathy in a National Football League player". *Neurosurgery* 57:128–34.
- Omalu BI, DeKosky ST, Hamilton RL, et al. (2006) "Chronic traumatic encephalopathy in a national football league player: part II". *Neurosurgery* 59:1086–93.
- Schwarz, Alan. "Study Says Brain Trauma Can Mimic Lou Gehrig's Disease", *The New York Times*, August 17, 2010.
- Zelman, PhD. Mark (2010). Human Diseases: A Systemic Approach. New Jersey: Pearson Education, Inc.
- Wikipedia:
http://en.wikipedia.org/wiki/Chronic_traumatic_encephalopathy
<http://en.wikipedia.org/wiki/Concussion>
http://en.wikipedia.org/wiki/Tau_protein
<http://en.wikipedia.org/wiki/TARDBP>